

Actinomycetes

- Gram-positive bacteria, many species with branching filaments
- Relatively slow growth on laboratory media
- Opportunistic pathogens producing diverse inflammatory responses

Actinomyces, Arcanobacterium and Actinobaculum species

-anaerobic or facultatively anaerobic
-morphologically heterogeneous
-non-spore-forming, non-motile
-MZN-negative
--colonize mucous membranes

Nocardia species

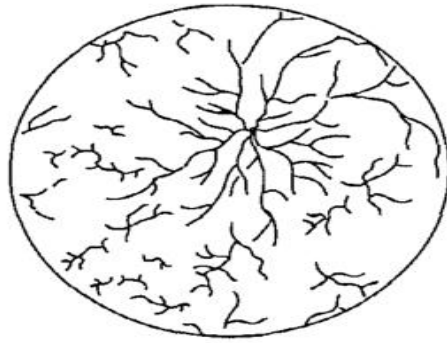
-aerobic, non-motile
-spores from aerial filaments
-growth on Sabouraud dextrose agar
-MZN-positive
-soil saprophytes

Dermatophilus congolensis

-aerobic and capnophilic
-motile zoospores
-no growth on Sabouraud dextrose agar
-found in scabs and in foci on skin of carrier animals

Actinomyces, Arcanobacterium and Actinobaculum species

Arcanobacterium pyogenes and *Actinobaculum suis* have a coryneform morphology whereas the *Actinomyces* species are usually long and filamentous although short V, Y and T configurations also occur.



Long branching filaments and shorter V, Y and T forms, typical of many Actinomyces species as they appear in smears from lesions.

Differentiation of the genera

Differentiating features of the genera are presented in the table below

Feature	<i>Actinomyces</i> species	<i>Arcanobacterium pyogenes</i>	<i>Actinobaculum suis</i>	<i>Nocardia</i> species	<i>Dermatophilus congolensis</i>
Atmospheric growth requirements	Anaerobic or facultatively anaerobic and capnophilic	Facultatively anaerobic and capnophilic	Anaerobic	Aerobic	Aerobic and capnophilic
Aerial filament production	-	-	-	+	-
Modified Ziehl-Neelsen staining	-	-	-	+	-
Growth on Sabouraud dextrose agar	-	-	-	+	-
Usual habitat	Nasopharyngeal and oral mucosae	Nasopharyngeal mucosa of cattle, sheep and pigs	Prepuce and preputial diverticulum of boars	Soil	Skin of carrier animals, scabs from lesions
Site of lesions	Many tissues including bone	Soft tissues	Urinary tract of sows	Thoracic cavity, skin and other tissues	Skin

Colonial morphology and haemolytic activity:

-*Arcanobacterium pyogenes* produces a characteristic hazy haemolysis along streak lines after aerobic incubation for 24 hours. Pin-point colonies become visible after 48 hours.

-*Actinomyces bovis* and *A. hordeovulneris* colonies typically adhere to agar media and are usually non-haemolytic.

-*Actinomyces viscosus* can produce two colony types, one large and smooth and the other small and rough.

The large colony is composed of V, Y and T cell configurations and the smaller colonies are formed of short branching filaments.

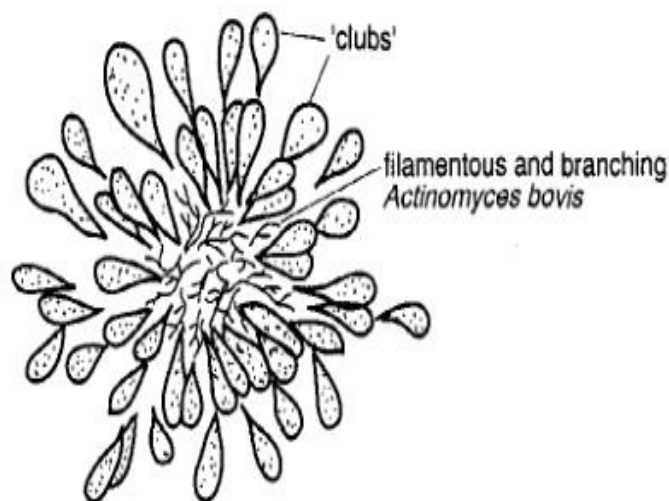
-*Actinobaculum suis* produces colonies which are up to 3 mm in diameter, with a shiny raised center and a dull edge. Poorly defined haemolysis is observed on ruminant blood agar.

Biochemical reactions

Specialized techniques, usually conducted in reference laboratories, are required for definitive identification of most of these fastidious, slow-growing organisms. In routine diagnosis, a presumptive identification of *A. pyogenes* is based on colonial morphology and pitting of a Loeffler's serum slope within 24 hours, which indicates proteolytic activity. It also hydrolyses gelatin.

Granules in pus

Granules can be detected when pus is diluted with distilled water in a Petri dish. In infections caused by *A. bovis*, pinhead-sized, yellowish 'sulphur granules' are found. Whitish, soft, grey granules are demonstrable in pus from animals infected with *A. viscosus*. Granules in lesions caused by *A. bovis* contain characteristic clubs (Fig. below). Club colony formation is a feature of other chronic infections such as bovine actinobacillosis caused by *Actinobacillus lignieresii* and botryomycosis usually associated with *Staphylococcus aureus*.



Urease is produced by *A. suis*.

Pathogenesis and pathogenicity

Actinobacterium pyogenes produces a haemolytic exotoxin which has dermonecrotizing activity and is lethal for laboratory animals. This bacterium also produces a protease and a neuraminidase, neither of which has a defined role in virulence. Toxin production by the other *Actinomyces* species has not been established. Purulent reactions are typical of infections with *A. pyogenes* whereas *A. bovis* and *A. viscosus* provoke pyogranulomatous reactions.

Diagnostic procedures

Clinical presentation, species affected and type and location of lesions may suggest the species involved.

Specimens suitable for laboratory procedures include exudates, aspirates and tissue samples for culture and histopathology.

Gram-stained smears may reveal morphological forms typical of the aetiological agent. Unlike *Nocardia* species, these bacteria are modified Ziehl-Neelsen (MZN) negative.

Histopathological examination of specimens from lesions caused by *A. bovis* reveals aggregates of filamentous organisms surrounded by eosinophilic club-shaped structures.

Blood and MacConkey agars are inoculated with the specimen and incubated at 37°C for up to 5 days. Species identification is difficult except in the case of *A. pyogenes*.

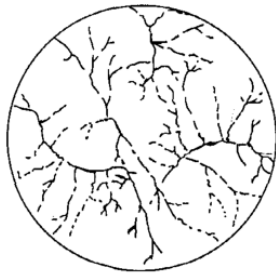
Clinical infections

The disease conditions produced by the pathogenic *Actinomyces*, *Arcanobacterium* and *Actinobaculum* species are presented in the table below.

Species	Hosts	Disease conditions
<i>Arcanobacterium pyogenes</i>	Cattle, sheep, pigs	Abscessation, mastitis, suppurative pneumonia, endometritis, pyometra, arthritis, umbilical infections
<i>Actinomyces hordeovulneris</i>	Dogs	Cutaneous and visceral abscessation, pleuritis, peritonitis, arthritis
<i>Actinomyces bovis</i>	Cattle	Bovine actinomycosis (lumpy jaw)
<i>A. viscosus</i>	Dogs	Canine actinomycosis: — cutaneous pyogranulomas — pyothorax and proliferative pyogranulomatous pleural lesions — disseminated lesions (rare)
	Horses	Cutaneous pustules
	Cattle	Abortion
<i>Actinomyces</i> species (unclassified)	Pigs	Pyogranulomatous mastitis
	Horses	Poll evil and fistulous withers
<i>Actinobaculum suis</i>	Pigs	Cystitis, pyelonephritis

Nocardia asteroides and other Nocardia species


Members of the *Nocardia* species are Gram-positive, aerobic, saprophytic actinomycetes. In smears of exudate from infected tissue, they appear as long, slender branching filaments with a tendency to fragment into rods and cocci. When cultured, these organisms produce aerial filaments which may form spores. Components of the cell wall, especially mycolic acid, render *Nocardia* species partially acid-fast (MZN-positive). In this genus, *Nocardia asteroides* is the pathogen of greatest significance in domestic animals.



Branching filaments of *Nocardia asteroides* as they appear in smears from lesions. The filaments have a tendency to fragment

Disease conditions produced by *Nocardia* species in domestic animals.

Species	Hosts	Disease conditions
<i>Nocardia asteroides</i>	Dogs	Canine nocardiosis: — cutaneous pyogranulomas — pyogranulomatous pleural lesions and pyothorax — disseminated lesions
	Cattle	Chronic mastitis, abortion
	Pigs	Abortion
	Sheep, goats, horses	Wound infections, mastitis, pneumonia, other pyogranulomatous conditions
<i>Nocardia farcinica</i>	Cattle	Bovine farcy ^a



Bovine farcy (is an uncommon cause of chronic lymphangitis, lymphadenitis, and cutaneous nodules).

Pathogenesis and pathogenicity

Infection, which is opportunistic, is usually associated with immunosuppression or, alternatively, may follow a heavy challenge. The usual mode of infection is by inhalation but it may also occur through skin wounds or via the teat canal. An intestinal form of nocardiosis may result from ingestion of the organisms.

Virulent strains of *N. asteroides* survive intracellularly. The production of superoxide dismutase and catalase and the presence of a thick peptidoglycan layer in the cell wall confer resistance to microbicidal activity of phagocytes.

Cell-mediated immunity is essential for protection against infection by this facultative, intracellular bacterium.

Diagnostic procedures

A presumptive diagnosis of infection with *N. asteroides* is based on clinical findings and laboratory procedures. Specimens suitable for laboratory examination include exudates, aspirates, mastitic milk, tissue from granulomas and fixed tissue for histopathology.

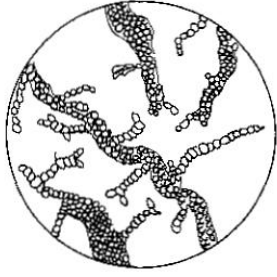
Smears of exudate should be stained by the Gram and MZN methods. *Nocardia asteroides* is MZN-positive, unlike *Actinomyces* species which are MZN-negative.

Histopathological examination of tissue specimens may reveal clusters of nocardial filaments.

The organism can be cultured on blood agar or on selective growth-enhancing media such as charcoal yeast extract medium. Plates are incubated aerobically at 37°C for up to 10 days.

Dermatophilus congolensis

Dermatophilus congolensis is a Gram-positive, filamentous, branching actinomycete with distinctive morphology.



Dermatophilus congolensis in a smear from scab material. Wide filaments contain coccal zoospores. Side branches divide into segments prior to the formation of zoospores.

Diagnostic procedures

The clinical picture is usually indicative of the infection, particularly in endemic areas. Specimens suitable for laboratory examination include scab material and samples of skin fixed in formalin.

Smears from the undersurface of scabs or from softened scab material, stained by the Giemsa method, reveal the characteristic branching filaments containing zoospores. When there is difficulty demonstrating the organism in smears, histopathological or immuno-fluorescent techniques may be employed.

Scab material softened with water can be cultured on blood agar at 37°C in an atmosphere of 2.5-10% CO₂ for up to 5 days.

Zoospores, which exhibit chemotaxis for CO₂, can be recovered from heavily contaminated specimens by placing infected scab material in distilled water at room temperature for 3.5 hours, followed by exposure to an atmosphere of CO₂ for 15 minutes. A sample from the surface of the water contains motile zoospores which can be cultured.

Infections with *D. congolensis* are usually confined to the epidermis.

Commonly used designations for infection with this organism are dermatophilosis and cutaneous streptothricosis. Mycotic dermatitis and wool are used to describe infection of woolled areas of the skin in sheep.

When the skin of the lower limbs of sheep is involved, the condition is termed strawberry foot rot.

Although the disease affects animals of all ages, it is more prevalent and often more severe in young animals.

Damage to the skin predisposes to infection with *D. congolensis*. Zoospores are most often transmitted by direct contact with infected animals.