

## Class : Sporozoa

### General characteristics:

All sporozoa are obligate parasites, they form temporary non-motile spores which contain infective cells. Four major groups are recognized on the basis of different spore morphology:

- >**Apicomplexan** parasites form distinctive oocysts containing infective sporozoites. Many species occur only in invertebrates whereas others may infect vertebrates causing severe diseases (such as malaria, tick fever, diarrhoea or abortion).
  
- >**Microsporan** parasites form unicellular spores containing coiled polar tubes used to infect host cells. Most species infect invertebrates (especially insects) although some form cysts in vertebrates (mainly fish).
  
- >**Haplosporidian** parasites form unicellular spores without polar filaments in the tissues of aquatic invertebrates. They cause significant morbidity and mortality in oysters throughout the world.
  
- >**Paramyxean** parasites form unique spore-within-spore arrangements within the tissues of bivalves and polychaetes. They cause QX and Aber disease in oysters.

## **Order : Coccidia**

### ***Eimeria spp.***

*Eimeria* is a genus of apicomplexan parasites that includes various species capable of causing the disease coccidiosis in cattle and poultry, among other animals.

### **Morphology and life cycle of the typical oocyst (*Eimeria spp.*):**

Coccidian parasites form three developmental stages: **schizonts, gamonts and oocysts.**

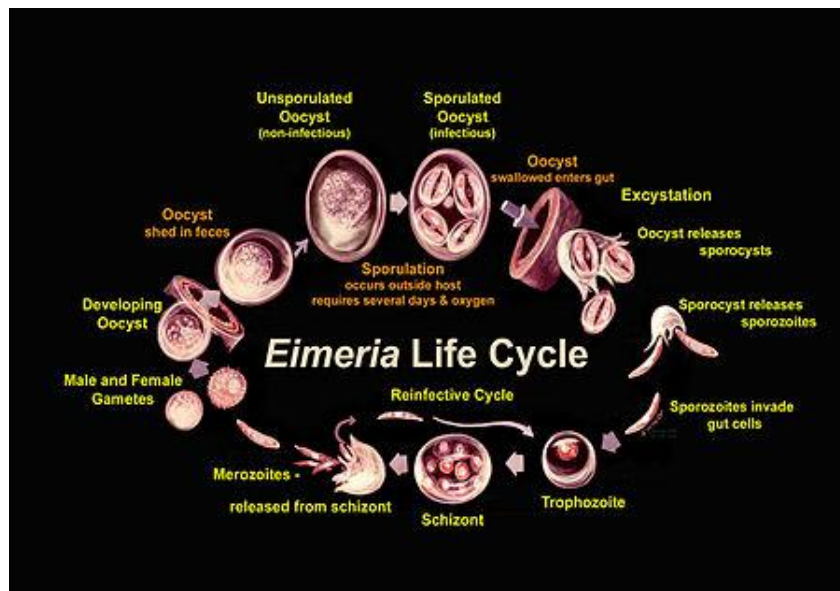
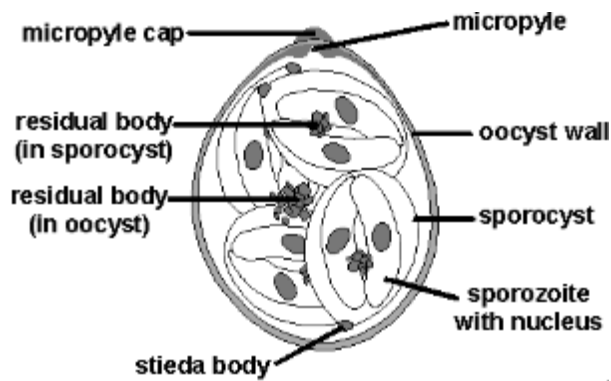
**Schizonts** range in size depending on parasite species, location in the host and stage of maturity. They begin as small basophilic rounded cells (mother meronts) located intracellularly within host cells.

**The meronts** form numerous daughter merozoites by endogenous division of the nucleus followed by cytokinesis. Mature schizonts appear as membrane-bound clusters of small basophilic bodies (similar to bunches of grapes). Individual schizonts usually range in diameter from 10-100µm but some species form enormous megaloschizonts (up to 1mm in diameter).

**Gamonts** exhibit sexual differentiation, with microgamonts (♂) apparent as multinucleate basophilic stages ultimately shedding small biflagellated microgametes; and macrogamonts (♀) evident as uninucleate eosinophilic cells with a single ovoid nucleus.

Developing **oocysts** contain numerous eosinophilic wall-forming bodies which give rise to the tough outer oocyst walls. Unsporulated oocysts contain a developing sporoblast which eventually undergoes sporulation

forming sporocysts which contain the infective sporozoites. *Eimeria* oocysts exhibit a characteristic 1:4:2 configuration, that is, each oocyst contains 4 sporocysts each containing 2 sporozoites. Oocysts are generally ovoid to ellipsoid in shape, range from 10-40µm in length by 10-30µm in width, and may contain specialized structures, such as polar caps, micropyles, residual and crystalline bodies.



## *Eimeria tenella*

This parasite develops in the cells of the ceca, which are the two blind sacs near the end of the intestine. It is one of the most pathogenic (disease producing) coccidia to infect chickens. This acute infection occurs most commonly in young chicks. Infections may be characterized by the presence of blood in the droppings and by high morbidity and mortality.

## *E.necatrix*

*E. necatrix* develops in the small intestine (early stages) and later in the cecum (sexual stages). Like *E. tenella*, it develops within deeper tissues of the small intestine and is a major pathogen of poultry.

### **How do Birds Become Infected?**

Normally, most birds pass small numbers of oocysts in their droppings without apparent ill effects. Coccidiosis becomes important as a disease when animals live, or are reared, under conditions that permit the build-up of infective oocysts in the environment. The intensive rearing of domestic chickens may provide these conditions.

**Young chickens** pick up the infection from contaminated premises (soil, houses, utensils, etc.). These premises may have been contaminated previously by other young infected birds or by adult birds that have recovered from the condition. Wet areas around water fountains are a source of infection.

### **How do Coccidia Harm Chickens?**

Several factors influence the severity of infection. Some of these include the following:

- **The number of oocysts eaten.** Generally, an increase in the number of oocysts eaten is accompanied by an increase in the severity of the disease.
- **Strain of coccidia.** Different strains of a species may vary in pathogenicity.
- Environmental factors affecting the survival of the oocysts.
- Site of development within the host. Coccidia that develop superficially are less pathogenic than those that develop deeper.
- **Age of the bird.** Young birds are generally more susceptible than older ones.
- Nutritional status of the host. Poorly fed birds are more susceptible.

Coccidiosis in chickens is generally classified as either intestinal or cecal. Most serious cases of intestinal coccidiosis are caused by *E. necatrix*. Cecal coccidiosis is due to *E. tenella*.

Coccidiosis occurs most frequently in young birds. Old birds are generally immune as a result of prior infection. Severe damage to the ceca and small intestine accompany the development of the coccidia. Broilers and layers are more commonly infected, but broiler breeders and turkey and pheasant poults are also affected.

### **How to Know When Chickens are Infected?**

The most easily recognized clinical sign of severe cecal coccidiosis is the **presence of bloody droppings**. **Dehydration** may accompany cecal coccidiosis.

Coccidiosis caused by *E. tenella* first becomes noticeable at about three days after infection. Chickens **droop**, **stop feeding**, **huddle together**, and by the fourth day, **blood begins to appear in the droppings**. The **greatest amount of blood** appears by day five or six, and by the eighth or ninth

day, the bird is either **dead or on the way to recovery**. **Mortality is highest between the fourth and sixth days**. Death may occur unexpectedly, owing to excessive blood loss. Birds that recover may develop a chronic illness as a result of a persistent cecal core. However, the core usually detaches itself by eight to ten days and is shed in the droppings.

*E. necatrix* causes a more chronic disease than *E. tenella* and does not produce as many oocysts. Therefore, a longer time is usually required for high levels of environmental contamination. Birds heavily infected with *E. necatrix* may die before any marked change is noticed in weight or before blood is found in the feces.

## **Diagnosis**

Signs, lesions, microscopic examination of scrapings.

## **Treatment**

Toltrazuril, Sulphonamides, Amprolium, Vitamins A and K in feed or water.

## ***Cryptosporidium* sp.**

*Cryptosporidium* is a microscopic parasite that causes the diarrheal disease cryptosporidiosis. Both the parasite and the disease are commonly known as "Crypto." The parasite is protected by an outer shell that allows it to survive outside the body for long period of time and makes it very tolerant to chlorine disinfection. While this parasite can be spread in several different ways, water (drinking water and recreational water) is the most common method of transmission. Many species of *cryptosporidium* exist that infect humans and wide rang of animals.

*Cryptosporidium parvum* and *C.hominis* are the most prevalent species. Development of cryptosporidium occurs within the brush border of the mucosal epithelial cells of the stomach & I.T. The clinical spectrum of the disease is wide, ranging from asymptomatic carriers, a self limited illness in immunocompetent persons, to cholera like illness in those infected with AIDS.

### **Morphology :**

The morphological form detectable in faeces is the oocyst measures 4-5 um in diameter, spherical or ovoidal in shape, containing four crescentic sporozoites and amylopectin like granules ( 1-6 large dark granules ).

### **Life cycle :**

*Cryptosporidium* has a **complex homogenous life cycle ( it is able to complete its cycle in a single host )**. An external period is not required for sporulation. Oocysts are excreted from the gut in infective form.

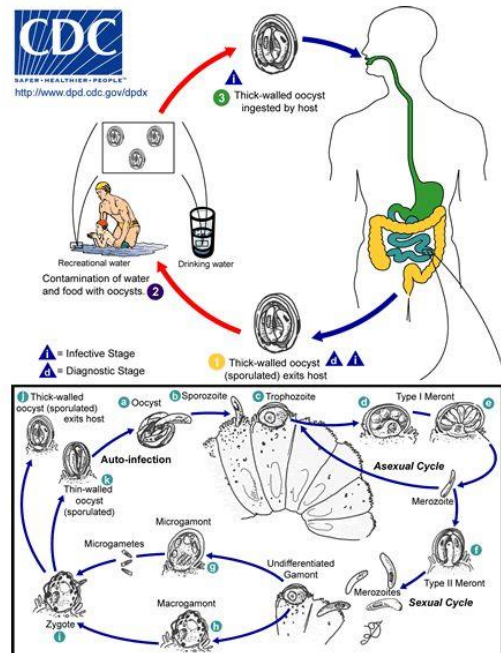
An incubation period 2-14 day follows ingestion of oocyst. **The infective stage is mature oocyst containing four sporozoites**. Excystation occurs in small intestine, sporozoites are released and invade the epithelial cells.

The first intracellular stage is trophozoite. The trophozoite undergoes three nuclear divisions to form a group of eight merozoites, to become first generation schizont. The merozoite released from the schizont infect other epithelial cells and develop into second generation schizont which is composed of only 4 merozoites. The second generation merozoites invade other epithelial cells and form microgametocytes & macrogametocytes. A microgametocyte produces 12-16 microgametes.

A macrogametocyte transforms into only one microgamete. After fertilization, zygote is formed and later develops into an oocyst.

Oocysts exist in two forms, thin walled and thick walled. **Thin walled oocysts reinfect the host ( autoinfection ) by attacking other** epithelial cell whereas thick walled oocysts are excreted out and infect new hosts.

# Life Cycle of *Cryptosporidium*



<http://www.dpd.cdc.gov/dpdx/HTML/Cryptosporidiosis.htm>

## Pathology and clinical findings

*Cryptosporidium* inhabits the brush border of mucosal epithelial cell of the gastrointestinal tract, especially the surface of villi of the lower small bowel. The prominent clinical feature of cryptosporidiosis is diarrhea, which is mild and self-limited (1-2 weeks) in normal persons but may be severe and prolonged in immunocompromised or very young or old individuals.

## Source of infection & Transmission

The transmission of *Cryptosporidium* spp is through ingestion of a thick wall oocysts that excreted in feces. The transmission of oocyst is either directly from infected human & animals or indirectly by contamination of environment with fecal materials such as water, food, air contamination.



The other source of infection is the sputum in pulmonary cryptosporidiosis . The most important routes of transmission are one of the following :

- 1- Person to person transmission
- 2- Zoonotic transmission
- 3- Food borne transmission
- 4- Waterborne transmission
- 5- Airborne transmission
- 6- Traveler's Diarrhea
- 7- Insect transmission
- 8- Accidental infection
- 9- Sexual transmission
- 10- Nosocomial transmission .

## **Diagnosis**

Diagnosis of cryptosporidiosis is made by examination of stool samples. Because detection of *Cryptosporidium* can be difficult, patients may be asked to submit several stool samples over several days. Most often, stool specimens are examined microscopically using different techniques (e.g., acid-fast staining, direct fluorescent antibody [DFA] , and/or enzyme immunoassays for detection of *Cryptosporidium* sp. antigens).

## **Treatment**

Anti-diarrheal medicine may help slow down diarrhea, but a healthcare provider should be consulted before such medicine is taken. Nitazoxanide has been FDA-approved for treatment of diarrhea caused by *Cryptosporidium* in people with healthy immune systems and is available

by prescription. However, the effectiveness of nitazoxanide in immunosuppressed individuals is unclear.

HIV-positive individuals who suspect they have cryptosporidiosis should contact their healthcare provider. For those persons with AIDS, anti-retroviral therapy that improves the immune status will also decrease or eliminate symptoms of cryptosporidiosis.

Lec.

- 1- the infective stage of Eimeria is .....
- 2- Eimeria is more effected on ..... Chicken
- 3- mention the clinical signs with *E. tenella*?
- 4- the oocyst of Eimeria has.....
- 5- the oocyst of Cryptosporidium has.....
- 6- the site of infection with Cryptosporidium in .....
- 7- Enumerate the Source of infection & Transmission of Cryptosporidium?

