



Tikrit University  
College of Veterinary Medicine

Subject name: Parasites

Subject year: 2024

Lecturer name: Trematoda

Academic Email:

[dr.omaimapara@tu.edu.iq](mailto:dr.omaimapara@tu.edu.iq)



SCAN ME

Lecturers link

## ***Fasciolopsis buski* (giant intestinal fluke)**

*Fasciolopsis buski* is a trematoda endoparasite, residing in the **small intestine of man and pig** causing a disease called “fasciolopsiasis. This parasite is considered to be the largest trematoda and generally called as “large or giant intestinal fluke”.

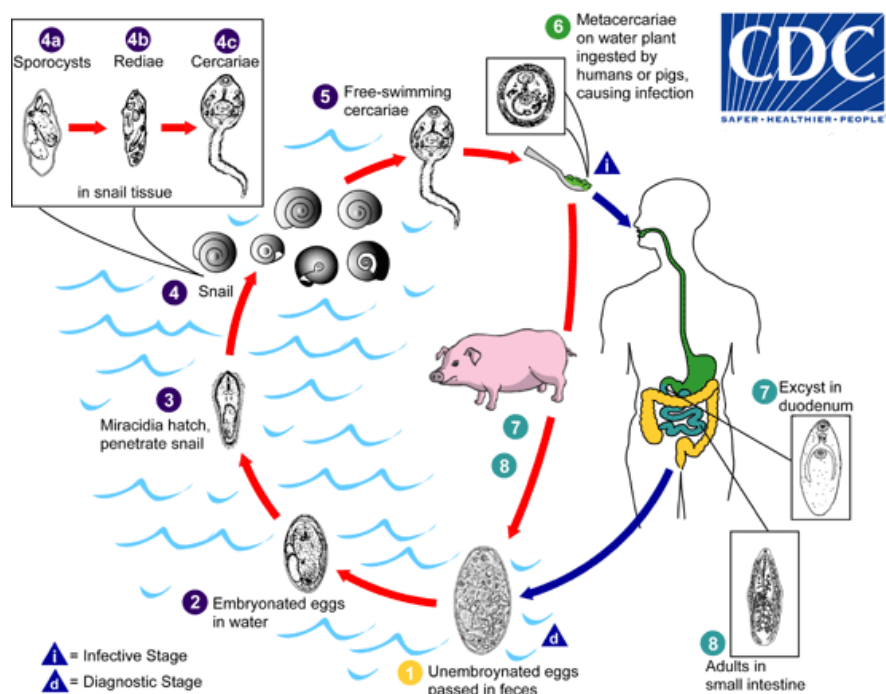
### **Main properties**

*Fasciolopsis buski* is considered one of the largest trematodes, with the adult form measuring approximately 60 mm in length. *Fasciolopsis buski* produce about 25,000 eggs per day, each oval and measuring approximately 130 µm in length. These eggs cannot be distinguished from the eggs of *Fasciola hepatica*.

### **Life cycle**

- The eggs from the uterus of the parasite are liberated into the lumen of the host’s intestine through their genital pore from where they pass out of the host body through faeces.
- Further development occurs only when the eggs fall into water or on damp soil.
- The egg hatches into first stage larva i.e, miracidium in 3 to 7 weeks at an optimal temperature of 27° to 32°C. The miracidium larva emerges through the opercular opening of the egg. After swimming actively in water for two hours, the miracidium penetrates the exposed soft parts of their secondary host snail of genus *Segmentina*.
- Inside the lymph spaces of the snail, the miracidium metamorphoses into next stage, the sporocyst. Redia larvae are formed inside sporocyst within three days.

- Cercaria larva leaves the snail body and after swimming for few hours encysts on fresh-water plants, especially the bulb of water chestnut, seed pods of water- caltrop and other aquatic vegetation grown in ponds fertilized by night soil. At this stage it is called, **metacercaria which is the infective stage.**



## Pathology and Symptoms

The disease caused by *F. buski* is known as fasciolopsiasis, which is characterized by mild anemia, chronic diarrhea and asthenia (Lack of strength and energy). The adult worm causes gastro-intestinal irritation, nausea and vomiting. At the point of attachment of the parasite to the intestinal wall, localized inflammation, hemorrhage and abscess may occur. Incubation period is 3 to 6 months.

## Diagnosis

Diagnosis is done primarily through microscopic identification of eggs in

stool samples or vomitus; however, *Fasciolopsis buski* eggs cannot be distinguished from the eggs of *Fasciola hepatica*. Although the eggs cannot be differentiated, one can determine the type of infection by the organs affected. *F. hepatica* infects the liver, while *F. buski* infects the small intestine. Occasionally the adult form can be identified in the samples as well.

### **Treatment:**

Tetrachlorethylene, thymol or hexylresorcinol are specific drugs. As these drugs may cause toxæmia, they should be used carefully.

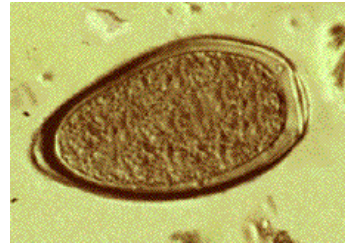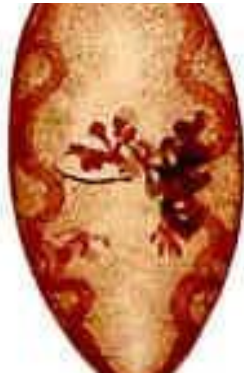## **\*Lung fluke**

### ***Paragonimus westermani* (oriental lung fluke)**

*P. westermani* usually are found in cysts, primarily in the lungs of dogs, cats, and several other domestic and wild animals. They also have been found rarely in other viscera or the brain. Infection is most common in China, southeast Asia, and North America. *P. westermani* is a parasite of people and other animals in China and other countries in the Far East.

### **Main properties**

The adult flukes are fleshy, reddish brown, oval, and  $\sim 14 \times 7$  mm. Adults have 2 muscular suckers, an oral sucker situated anteriorly and a ventral sucker at mid body on the ventral surface. The eggs are golden brown, oval, distinctly operculated, and  $\sim 100 \times 60$   $\mu\text{m}$ .



### **Life cycle**

- Eggs passed in sputum or feces develop for 2 to 3 wk in freshwater before miracidia (first larval stage) hatch.
- The miracidia invade snails; there, they develop, multiply, and eventually emerge as cercariae (free-swimming larvae).
- Cercariae penetrate freshwater crabs or crayfish and encyst to form metacercariae.
- Humans and animals become infected by eating raw, pickled, or poorly cooked crustaceans. Metacercariae excyst in the host GI tract, penetrate the intestinal wall, and move into the peritoneal cavity, then through the diaphragm into the pleural cavity; they enter lung tissue, become encapsulated, and develop into hermaphroditic adult worms.

### **Pathogenicity and clinical signs**

Disease most frequently involves the lungs as adult flukes living in the lung cause lung disease. Initial signs and symptoms may be diarrhea and abdominal pain followed several days later by fever, chest pain, and fatigue. The symptoms may also include a dry cough, which later becomes productive with rusty-colored or blood-tinged sputum on exertion, and pleuritic chest pain.. Extrapulmonary disease is not uncommon, with flukes found in such sites as the CNS, subcutaneous tissues, intestinal wall, peritoneal cavity, liver, lymph nodes and genitourinary tract. Infection usually lasts for years, and the infected

person may be asymptomatic. The symptoms of paragonimiasis can be similar to those of tuberculosis, clinically and on chest X-rays.

### **Clinical signs**

- 1- During invasion and migration of the flukes, diarrhea, abdominal pain, fever, cough, urticaria, hepatosplenomegaly, pulmonary abnormalities, and eosinophilia may develop.
- 2- During the chronic phase, the lungs are damaged most, but other organs may be involved. Manifestations of pulmonary infection develop slowly and include chronic cough, chest pain, hemoptysis, and dyspnea; the clinical picture resembles and is often confused with TB.
- 3- Cerebral infections manifest as space-occupying lesions, often within a year after the onset of pulmonary disease. Seizures نوبات مرضية, aphasia عدم القدرة على الكلام, paresis شلل جزئي, and visual disturbances occur.

### **Diagnosis**

- Diagnosis is by identifying the characteristic large operculated eggs in sputum or stool. Concentration techniques increase sensitivity.
- Serologic tests to detect antibodies are useful in light infections and in the diagnosis of extrapulmonary paragonimiasis.
- X-rays provide ancillary information but are not diagnostic; chest x-rays and CT may show a diffuse infiltrate, nodules, annular ring shadow lesions, cavitations, linear opacities, lung abscesses, pleural effusion, and pneumothorax.

### **Treatment**

Praziquantel is the drug of choice. Triclabendazole for severe infections. Surgery may be needed to excise skin lesions or, rarely, brain cysts.

