



Tikrit University  
College of Veterinary Medicine

# Tumor tissue

# connective

Subject name: Practical Pathology

Subject year: 2024-2025

Lecturer name: Thamer J. Shihab

Academic Email:

[dr.thamer.vet@tu.edu.iq](mailto:dr.thamer.vet@tu.edu.iq)



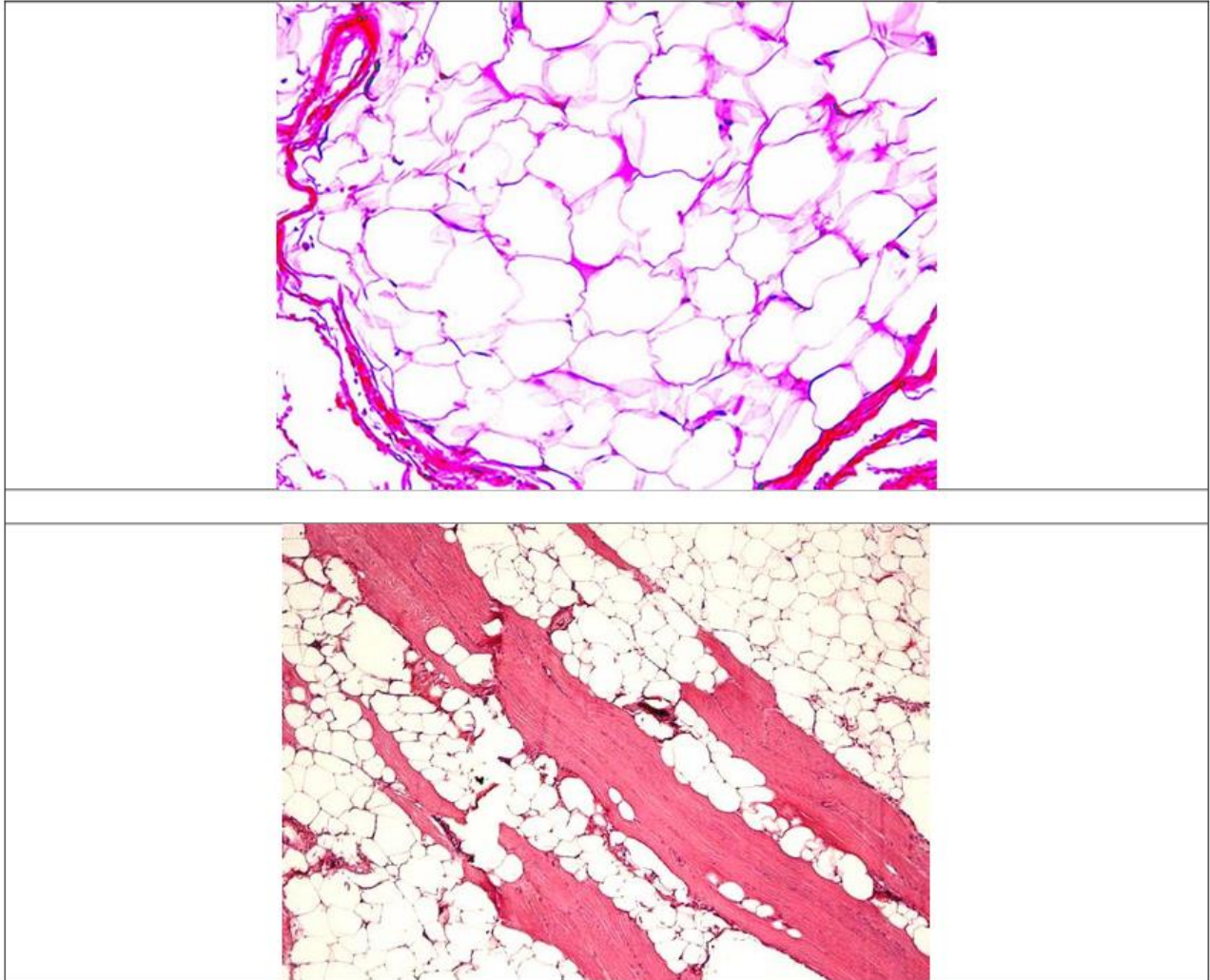
SCAN ME

Lecturers link

**Organ:** Connective tissue

**Lesion:** The section shows, the nucleus is pushed to the periphery or even destroyed.  
Interspersed between the fat cells are strands of collagen fibers.

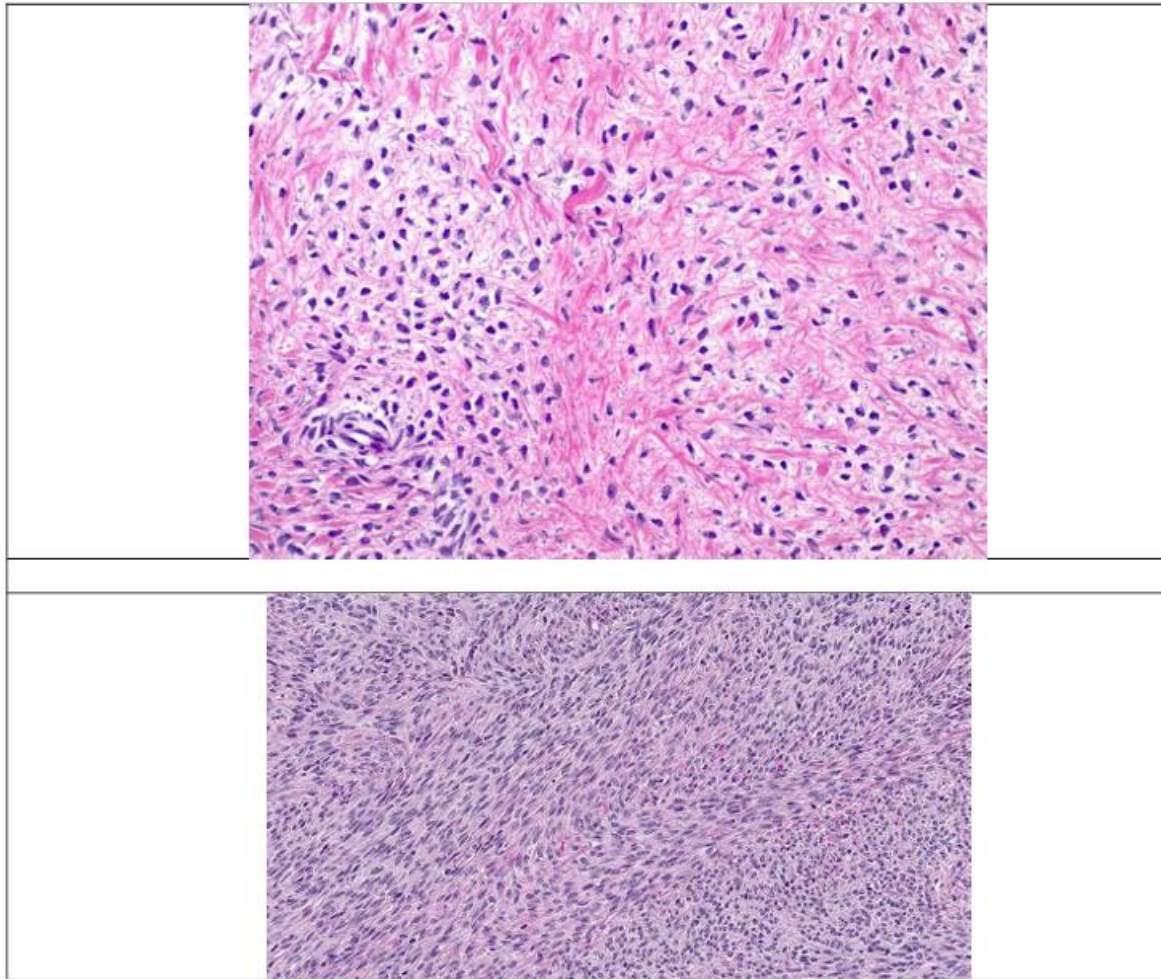
**Diagnosis:** Lipoma



**Organ:** Connective tissue

**Lesion:** The section shows, the cells, and their nuclei are spindle-shaped. The collagen fibers are seen as compact bundles of wavy fibers, arranged in a concentric manner around blood vessels.

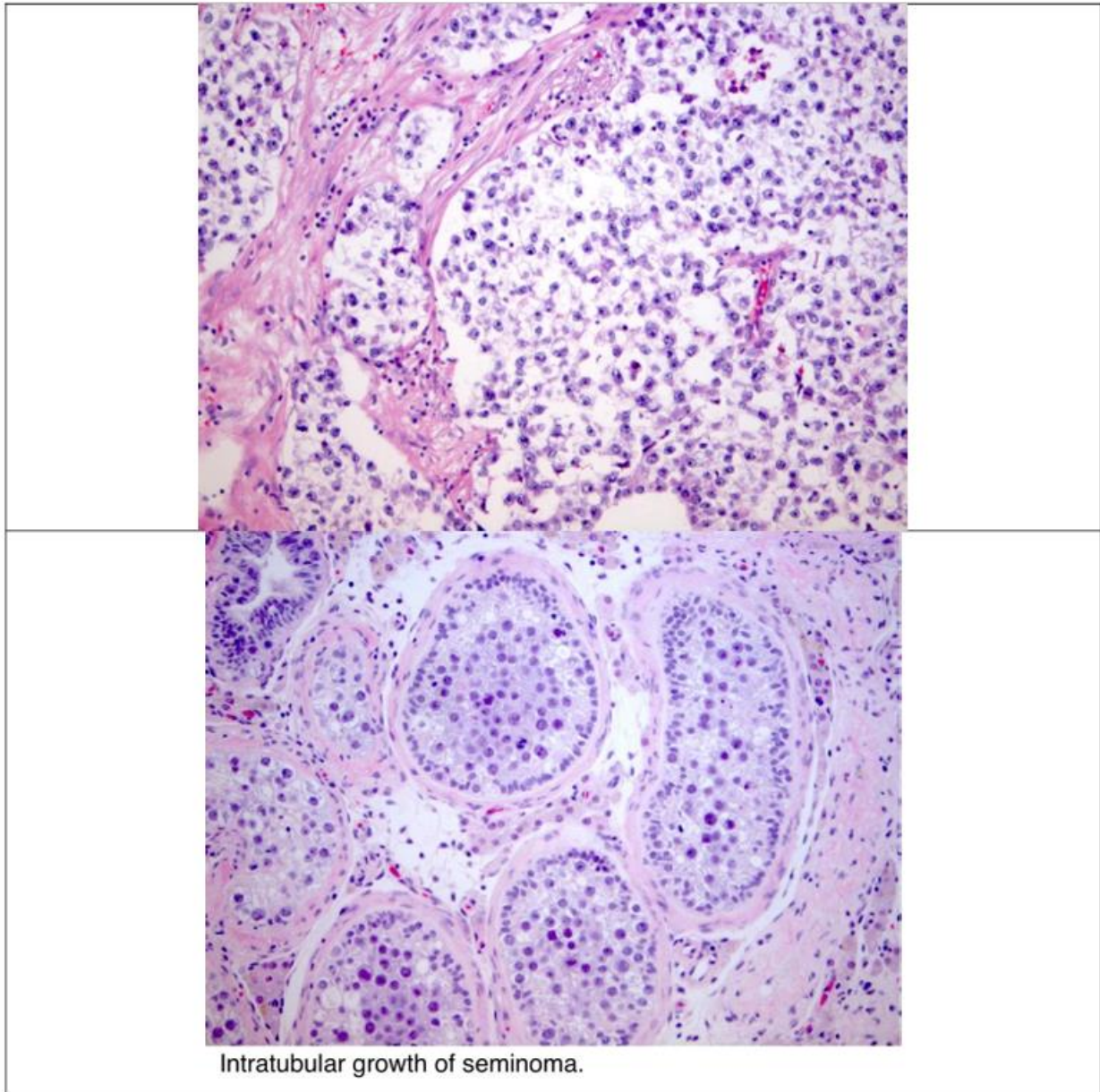
**Diagnosis:** Fibroma



**Organ:** Testis

**Lesion:** The section shows, the seminoma is composed of polyhedral cells with prominent, hyperchromatic round nuclei. Mitotic figures are numerous. Multiple nuclei may be found within the cell. Fine trabeculae divide the masses of cells into compartments.

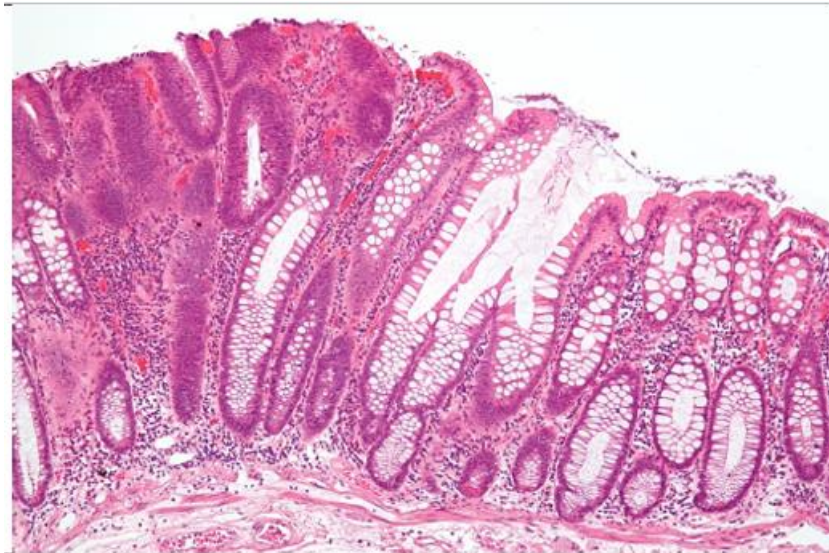
**Diagnosis:** Seminoma



**Organ:** Oral

**Lesion:** The section shows, adenomas look very much like the gland from which they originate. The amount of glandular tissue is more and the acini are lined with more than one layer of cells. Sometimes secretions are retained in the acini, causing them distended, and their epithelium to undergo atrophy.

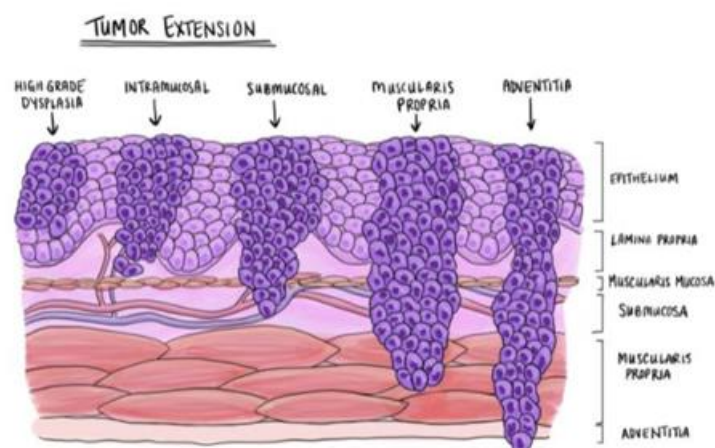
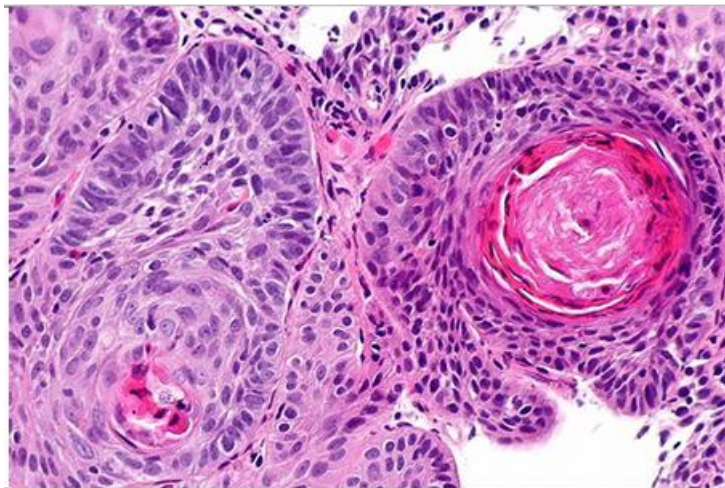
**Diagnosis:** Adenoma



**Organ:** Esophagus

**Lesion:** The section shows, Tumour arranged in cribriform lobules with solid nests of neoplastic cells are infiltrating down through the sub-mucosa, and have abundant pink cytoplasm and distinct cell borders typical for squamous cell carcinoma.

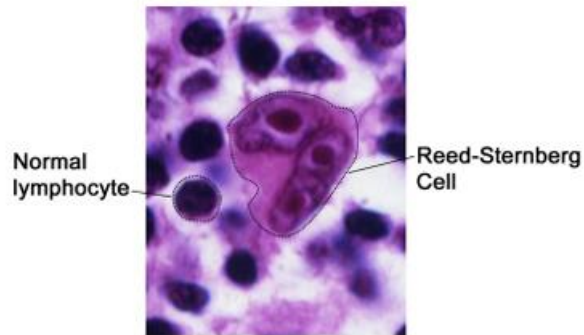
**Diagnosis:** Esophageal squamous cell carcinoma



**Organ:** Connective tissue

**Lesion:** The section shows, Reed-Sternberg cells are large, abnormal lymphocytes (a type of white blood cell) that may contain one or more than one nucleus.

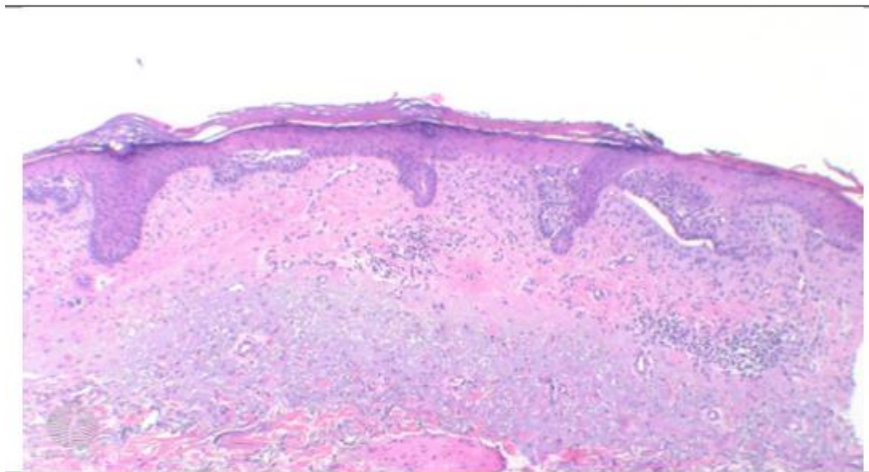
**Diagnosis:** Hodgkin lymphoma (Reed-Sternberg cell)

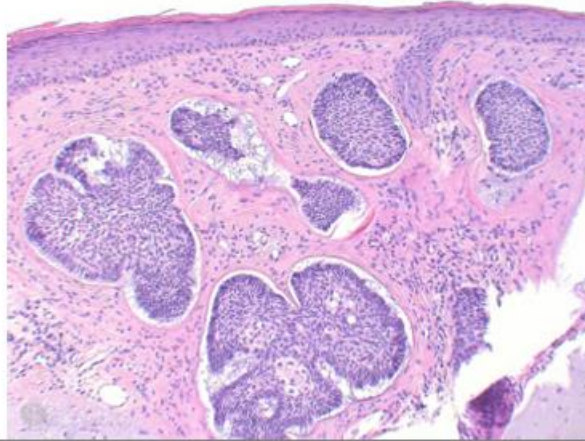


**Organ:** Skin

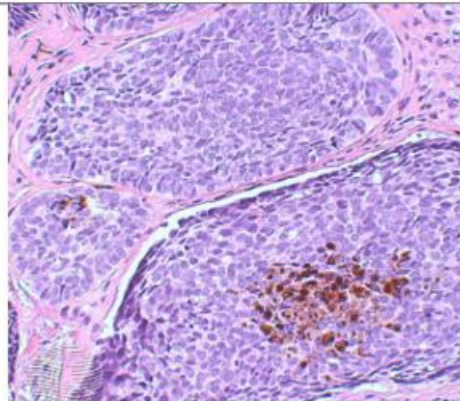
**Lesion:** The section shows, multifocal nests of atypical basaloid epithelium arising as buds from the basal layer of the epidermis with presence of peripheral palisades. variable mitotic activity.

**Diagnosis:** Basal cell carcinoma





The tumour forms a solid tumour nodule or nodules which may extend into subcutaneous tissues. Cartilaginous invasion is unusual



Pigmented BCC: Focal deposits of melanin are evident throughout the tumour. An increased number of melanocytes may also be seen within the tumour, and scattered melanophages may be present in the surrounding stroma