



Tikrit University
College of Veterinary Medicine

Trichomoniasis

Subject name: Poultry Diseases

Subject year:2024

Lecturer name: Nawar Ali Jasim

Academic Email:pdvet10@tu.edu.iq



1

SCAN ME
Lecturers link

Protozoa Diseases

There are Four important protozoan diseases of Poultry:-

1-**Trichomoniasis** caused by Trichomonas gallinae.

2-**Histomoniasis (Blackhead)** caused by Histomonas meleagridis.

3-**Avian Toxoplasmosis** caused by Toxoplasma gondii.

4-**Coccidiosis** spp.

1- Trichomoniasis

***Definition:** It is a **protozoan** disease of birds, affecting the **upper digestive tract**, In **Pigeons**, it causes a condition known as **Canker**.

***Etiology:** caused by Trichomonas gallinae, it has four flagella and rapidly moving, **pear-shaped protozoa**.

***Susceptibility:-**

Turkeys, Chicken, and a wide variety of **wild birds** are parasitized with varying degrees of pathogenicity.

***Incidence and Distribution:-**

1-In Pigeons, **Squabs** (young birds) usually become infected with their first taste of "**Pigeon milk**" from the **crop** of adults and usually remain **carriers** throughout life.

2-**Mortality** with virulent strains, may reach **50%** before sufficient protective immunity develops.

3-**Pigeons** are often blamed (responsible) for transmission of trichomoniasis to **turkeys** and **chickens** and (**falcons** which feed on pigeons), the infection known as "frounce" among falconers.

4-In Chicken and turkeys flocks, infection is spread by contamination of **drinking water** and perhaps feed.

***Clinical Signs: -**

1-Affected birds may **cease to feed** and become listless, ruffled feather, and **emaciation before death**.

2-A **greenish to yellowish fluid** may be seen in **oral cavity** and may **drip** from the **beaks** of infected birds.

***Gross lesion:-**

1- *T. gallinae* invade the mucosal surface of the **buccal cavity**, Sinuses, Pharynx, **esophagus** and **crop** and Occasionally the Conjunctiva and Proventriculus.

2- The liver is frequently invaded and occasionally other organs, but **not** the digestive tract bellows the proventriculus.

3-The lesions appear initially as **small, circumscribed Caseous areas** on the surface of the oral mucosa, which may be surrounded by a thin zone of hyperemia.

4-The **Caseous material** may be sufficient to **occlude** the lumen of the **esophagus** partially or completely.

5-These lesions may be **penetrate** tissue and involve other regions of the **head and neck**.

6-The **liver** lesions appear on the surface and extend into the parenchyma as **solid, white to yellow circular** or spherical **masses**.

***Microscopic lesions:-**

1-Pigeons infected with a virulent strain of *T. gallinae* had **purulent inflammation** with **caseous necrosis**.

2-Trichomonads multiply in **secretions** and on the mucosal surface of the **oropharynx**.

3-**Ulceration** of the **mucosa** with a massive inflammatory response, primarily **heterophils**, is well established by the **fourth day** of experimental infections.

4- In the **liver**, **focal necrotic abscesses** occurred in all zones of lobules, with an inflammatory reaction characterized by mononuclear cells and **heterophils**.

5- As **liver** lesions progressed, no intact **hepatocytes** remained in the **center of foci**; **trichomonads** were most numerous **at the periphery**.

***Diagnosis:-**

1-Clinical Signs and gross lesions are highly important.

2-microscopic observation of organisms in **direct wet smears** from the **mouth** or **crop**.

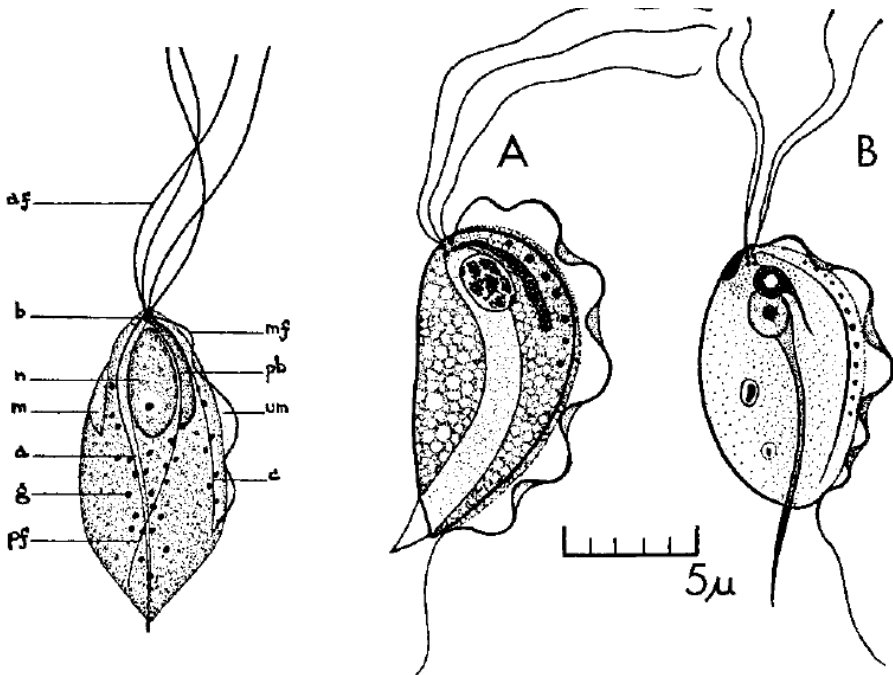
3- Trichomoniasis must be **differentiated from candidiasis** and **hypovitaminosis-A**, which can produce similar lesions.

***Control and prevention:**

1-Because T. gallinae is transmitted from **parent** to **squab** in pigeons and by contamination of feed and **water** by oral fluids to domestic fowl (Chicken, turkeys), **sick birds** should be **removed from a flock**.

2- **Drugs** with activity against other related protozoa (H. meleagridis, Entamoeba histolytica, Giardia lamblia) are active against trichomoniasis in pigeons or turkeys.

2- **Dimetridazole** useful at a level of **0.05%** in drinking water for pigeons.



28.14. *Trichomonas gallinae*, semi-diagrammatic (left): (a) axostyle, (af) anterior flagellum, (b) blepharoplast, (c) costa, (g) cytoplasmic granules, (m) mouth, (mf) marginal filament, (n) nucleus, (pb) parabasal body, (pf) parabasal fibril, (um) undulating membrane (Stabler). Two common trichomonads of the lower digestive tract of domestic birds (right), as specimens fixed in Schaudinn's fluid and stained with Heidenhain's hematoxylin may appear. A. *Tritrichomonas eberthi*. B. *Trichomonas gallinarum*. (Lund)

Referens:

1-Saif, Y. M. (2009). *Diseases of poultry*. Twelfth edition. Iowa. Blackwell.2009. 1067-1120.