



Surgery



Tikrit University
College of Veterinary Medicine

Digestive System

Salivary Glands

Subject name: Surgery

Subject year: 5th stages

Lecturer name: Dr. Montaser M. Helal

Academic Email:

Montaser.helal1981@tu.edu.iq



SCAN ME

Lecturers link

Salivary Glands

ANATOMY

The salivary glands in dogs and cats are categorized as major or minor, depending on their size and location of saliva.

The four major salivary glands in dogs and cats are

- 1- the parotid,
- 2- mandibular,
- 3- sublingual,
- 4- zygomatic

The minor salivary glands are named by their location and drain directly into the oral cavity.

Parotid Gland

The parotid gland is a triangular-shaped gland positioned superficial to the vertical ear canal.

It is bordered rostrally by the masseter muscle and the temporomandibular joint, caudally by the sternomastoideus and cleidocervicalis muscles, ventrally by the mandibular salivary gland, and superficially by the parotidoauricularis and platysma muscles.

It is covered by a thin capsule.

The parotid duct travels over the lateral aspect and ventral third of the masseter muscle and opens into the oral cavity through a small papilla at the level of the upper fourth premolar.

Zygomatic Gland

The zygomatic gland (also known as the dorsal buccal gland) is located in the periorbital area just ventral and rostralateral to the globe and medial to the zygomatic arch.

One major and up to four minor salivary ducts are sent from the zygomatic gland into the oral cavity.

The major duct opens into the oral cavity at the caudal aspect of the last upper molar.

The zygomatic papilla is about 1 cm caudal to the parotid salivary papilla.

Mandibular and Sublingual Salivary Gland

Mandibular and sublingual salivary glands are intimately associated and thus considered anatomically as a pair.

Mandibular Salivary Gland

The mandibular salivary gland is a large, palpable gland located caudomedially to the angle of the mandible.

It lies on the medial aspect of the junction of the linguofacial and maxillary veins.

Sublingual Salivary Gland

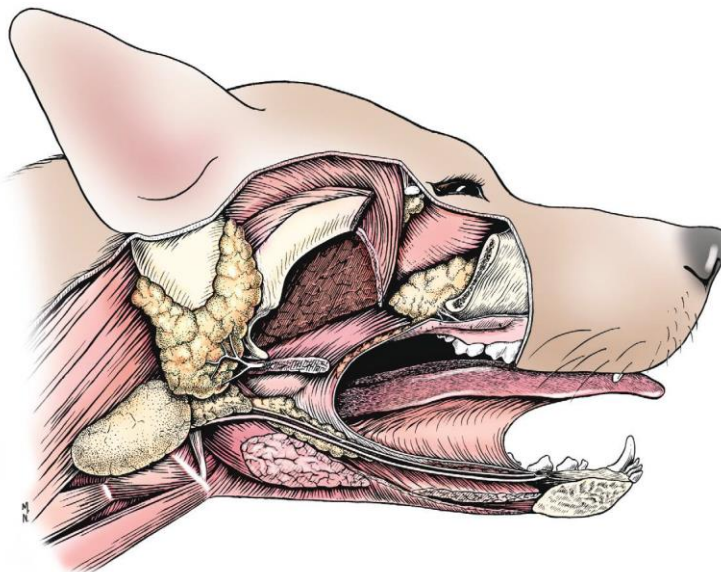
The sublingual salivary gland found within the capsule shared by the mandibular salivary gland.

It has a large portion that abuts the mandibular salivary gland and tapers to a triangular shape rostrally. External to the capsule, the gland continues rostrally in close association with the mandibular.

Sublingual salivary duct courses alongside the mandibular duct and usually exits at the sublingual caruncle just caudal to the mandibular duct.

Minor Salivary Glands

The minor salivary glands are typically small collections of salivary tissue surrounding the oral cavity that drain their secretions directly into the oral cavity to keep it moist. These glands include the buccal, labial, lingual, tonsillar, palatine, and molar. The molar gland is well developed in cats and is located just deep to the buccal mucosa at the angle of the mandible.



PHYSIOLOGY

Salivary glands in dogs and cats produce saliva that primarily functions to

- 1- lubricate ingesta and facilitate packaging of a food bolus for its passage down the esophagus.
- 2- thermoregulation (evaporative cooling),
- 3- oral cavity cleansing,
- 4- buffering of weak acids,
- 5- reduction of oral bacterial growth,
- 6- protection of surface epithelium in the oral cavity.

NONSURGICAL SALIVARY GLAND DISEASE

Sialadenosis

Sialadenosis is a noninflammatory swelling of the salivary glands, most commonly affecting the mandibular salivary glands.

Clinical signs

hypersalivation, and weight loss.

Affected glands are enlarged but are usually **nonpainful**.

Treatment with 1 to 2 mg/kg of phenobarbital twice a day, however, may improve clinical signs within 1 to 2 days.

Sialadenitis and Necrotizing Sialometaplasia

Salivary glands can develop inflammation (sialadenitis) that occasionally progresses to glandular necrosis and ductal metaplasia.

Clinical signs

very similar to sialadenosis, with the addition of **pain upon palpation of the affected glands and vomiting.**

The diagnosis is based on histologic findings of lobular necrosis, inflammation, squamous metaplasia, infarction, and hypertrophy of ductal epithelium.

Because esophageal or gastrointestinal disease has been identified concurrently with necrotizing salivary gland disease.

SURGICAL SALIVARY GLAND DISEASE

Sialocele

Sialoceles, also termed *salivary mucoceles*, are collections of saliva within subcutaneous tissue.

Resultant saliva-filled cavities are lined by inflammatory connective tissue and are not true cysts.

The most common source of saliva is leakage from the sublingual salivary gland or duct, but origination from any gland is possible.

Sialoceles have reportedly been caused by trauma, sialoliths, foreign bodies, and neoplasia; however, the majority have an unknown cause.

The four main presentations are

- 1- exophthalmos (zygomatic sialocele)
- 2- labored breathing (pharyngeal sialocele);
- 3- dysphagia (sublingual sialocele or ranula);
- 4- intermandibular or cranioventral cervical swelling (cervical sialocele).

Diagnosis of sialoceles

usually based on clinical signs of a fluid-filled mass that contains a viscous, clear or blood-tinged fluid on aspirate.

Treatment of Ranulas

Sublingual sialoceles (ranulas) are treated by remove of the fluid-filled pocket and removal of the mandibular and sublingual salivary gland complex.

A large full-thickness oval area of the tissue overlying the sublingual sialoceles is excised.

The remaining external (oral) mucosa is sutured to the lining of the sialoceles with small-gauge, absorbable, monofilament suture.

The mucosal edge is folded inward and sutured in place.

This prevents exposed edges of mucosa from coming into contact.

Because there is not a true epithelial lining of the sialocele, to prevention of recurrence can only be ensured by removal of the glandular source of saliva within the sialocele.

Sialoliths

Sialoliths are most often associated with the parotid duct but have also been reported in the mandibular–sublingual duct complex.

Stone compositions may include **calcium, oxalate, phosphate, magnesium, carbonate, ammonium, or nonmineral proteinaceous material.**

Stone like structures identified within a sialocele composed into the duct lumen. Affected animals usually have a swelling on the lateral aspect of the face that may be painful and may regress and then reoccur.

Diagnosis of a salivary sialolith

can be made by palpation or on radiographs; however, CT usually provides more specific information.

Sialoliths can be treated by several strategies, including gland and duct removal, duct ligation, duct resection and anastomosis, marsupialization of the dilated duct into the oral cavity, and incision over the stone for removal with primary duct repair or no repair.

Treatment of Sialoliths

The affected duct– gland complex can be surgically removed along with the sialolith if the sialolith originates from an easily removable complex such as the mandibular and sublingual salivary gland.

If the sialolith is close to the papilla or palpable within the oral cavity, an incision can be made through the mucosa directly over the stone. The incision is left to heal by second intention.

Sialoliths have also been successfully treated by complete ligation of the duct, resection and anastomosis, and primary repair of the affected duct.

If duct dilatation is the primary clinical sign, open of the duct into the oral cavity has been reported as a successful option.

Salivary Gland Neoplasia

The mandibular and parotid salivary glands are most commonly affected.

Tumor invasion into local tissues and spread to regional lymph nodes occasionally occur.

clinical signs, including a unilateral, nonpainful, firm swelling in the region of the upper neck, base of the ear, and upper muzzle or maxilla; halitosis; exophthalmos; and dysphagia.

Diagnostic evaluation of these animals should include sampling of the mass and regional lymph nodes (needle or incisional biopsy) and three-view thoracic radiographs for metastases.

Blood work and abdominal ultrasonography should be performed if clinically indicated. CT and MRI can be extremely valuable with preoperative surgical planning of locally invasive disease.

The treatment by remove the gland.

SURGICAL TECHNIQUES

Sublingual and Mandibular Sialadenectomy

Sublingual and mandibular sialadenectomy is one of the most common surgical procedures performed on the salivary glands because most sialoceles originate from this duct–gland complex.

- 1- The animal is positioned in dorsal recumbency,
- 2- A large area from the midcervical region to the most rostral portion of the ventral mandible is clipped and aseptically prepared.
- 3- An incision is made starting from a point 4 to 5 cm caudal to the mandibular ramus on the affected side and extending rostrally toward the mandibular symphysis.

- 4- If bilateral gland removal is to be performed, a midline incision can be made.
- 5- The platysma muscle is incised to facilitate identification of the external jugular bifurcation;
- 6- The mandibular gland sits at or just cranial to the venous bifurcation.
- 7- Tissues are bluntly dissected to expose the capsule covering the mandibular and sublingual salivary glands.
- 8- The salivary glands must be differentiated from mandibular lymph nodes, which are more rostral and ventral at this location.
- 9- The capsule over both glands is incised and bluntly dissected off the glandular tissue to facilitate ligation of vessels on the medial side of the gland
- 10- The gland complex is then retracted caudally to allow blunt dissection of the sublingual gland under (dorsal to) the digastricus muscle
- 11- With a hemostat placed from rostral to caudal under the digastricus muscle, the ducts are clamped just rostral to the large glandular complex
- 12- The remaining ducts and sublingual glands are pulled under the digastricus muscle. Blunt dissection is continued rostrally to the level of the lingual nerve
- 13- The mylohyoideus muscle needs to be incised for best exposure of the rostral glandular tissue and lingual nerve
- 14- The duct is ligated as rostrally as possible and transected.
- 15- The mylohyoideus, platysma muscle, and subcutaneous tissues are reapposed with an absorbable monofilament suture.